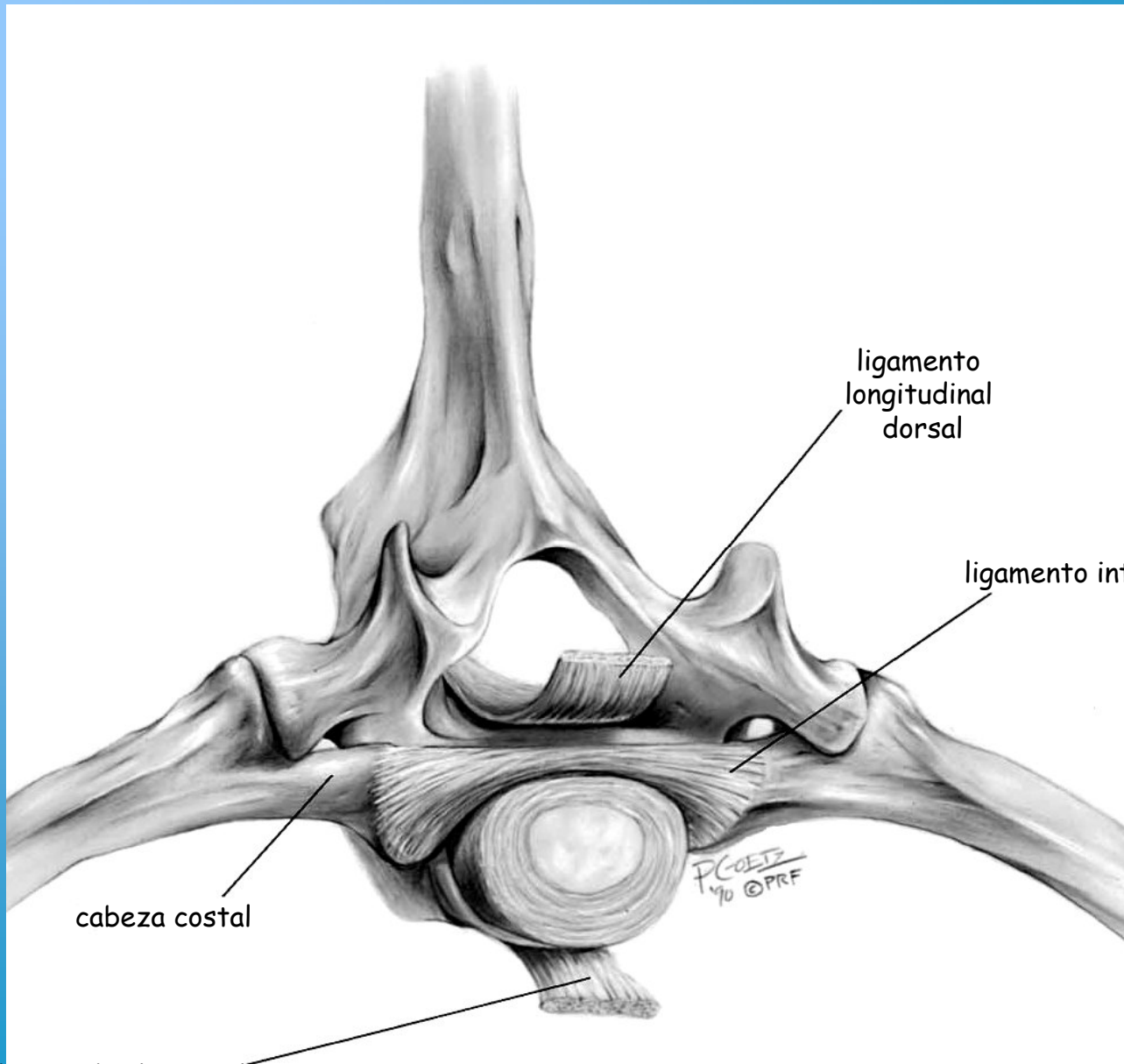


*Anatomía del
canal vertebral
y la médula espinal*

Dr. Fernando Pellegrino

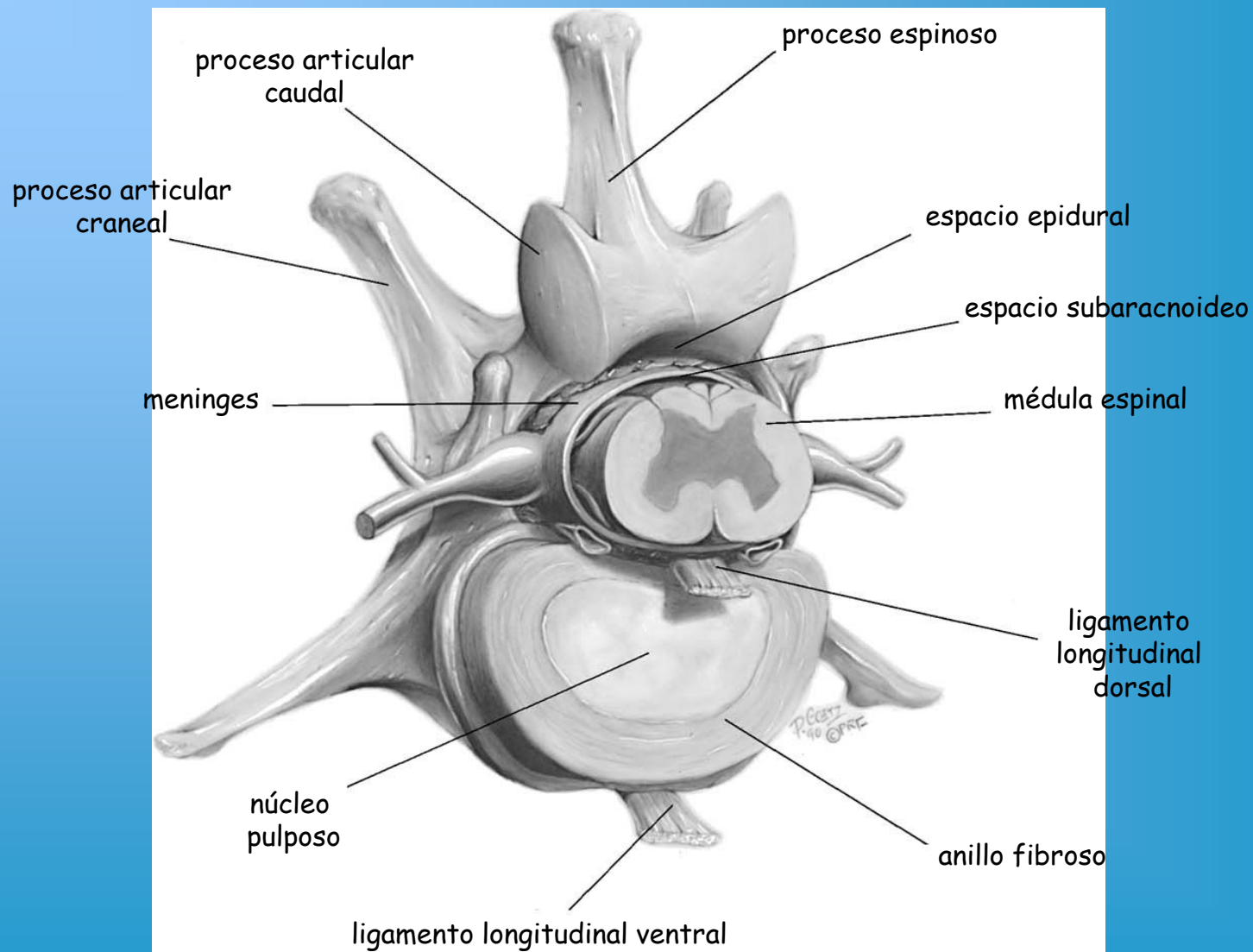


ligamento longitudinal dorsal

ligamento intercapital

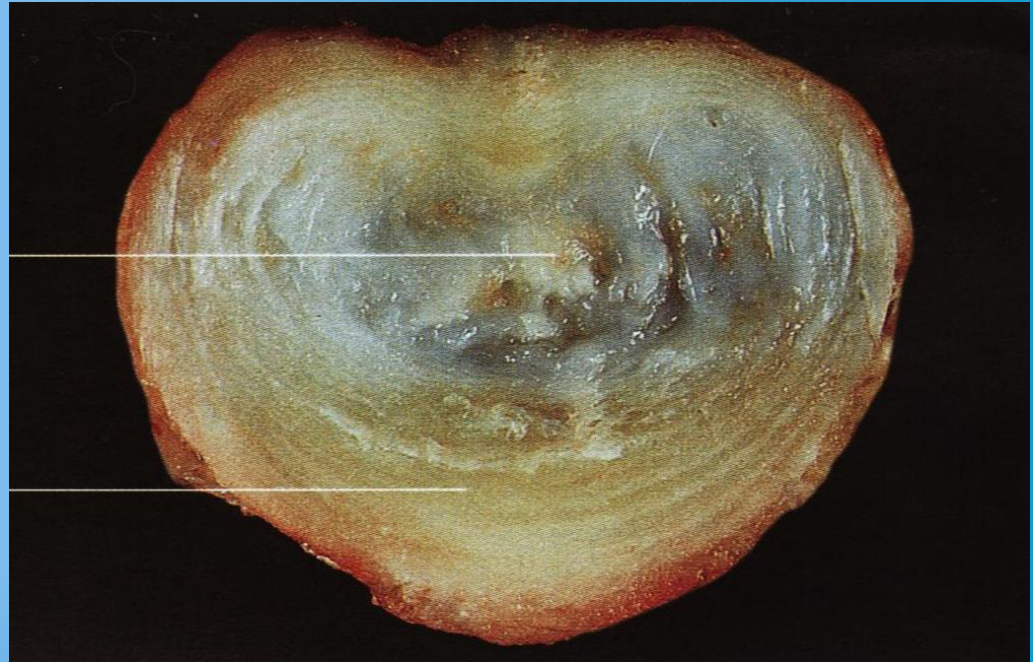cabeza costal

ligamento longitudinal ventral



núcleo pulposo

anillo fibroso

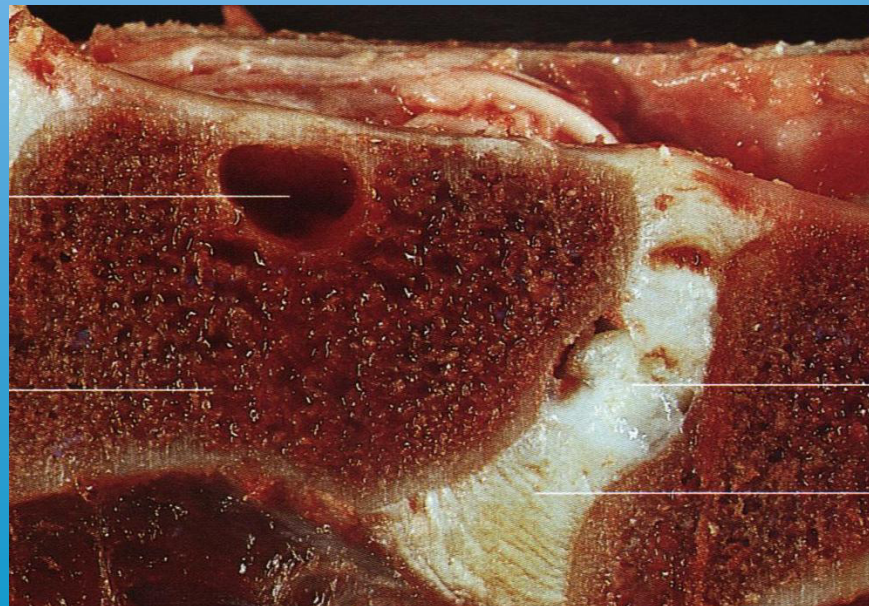


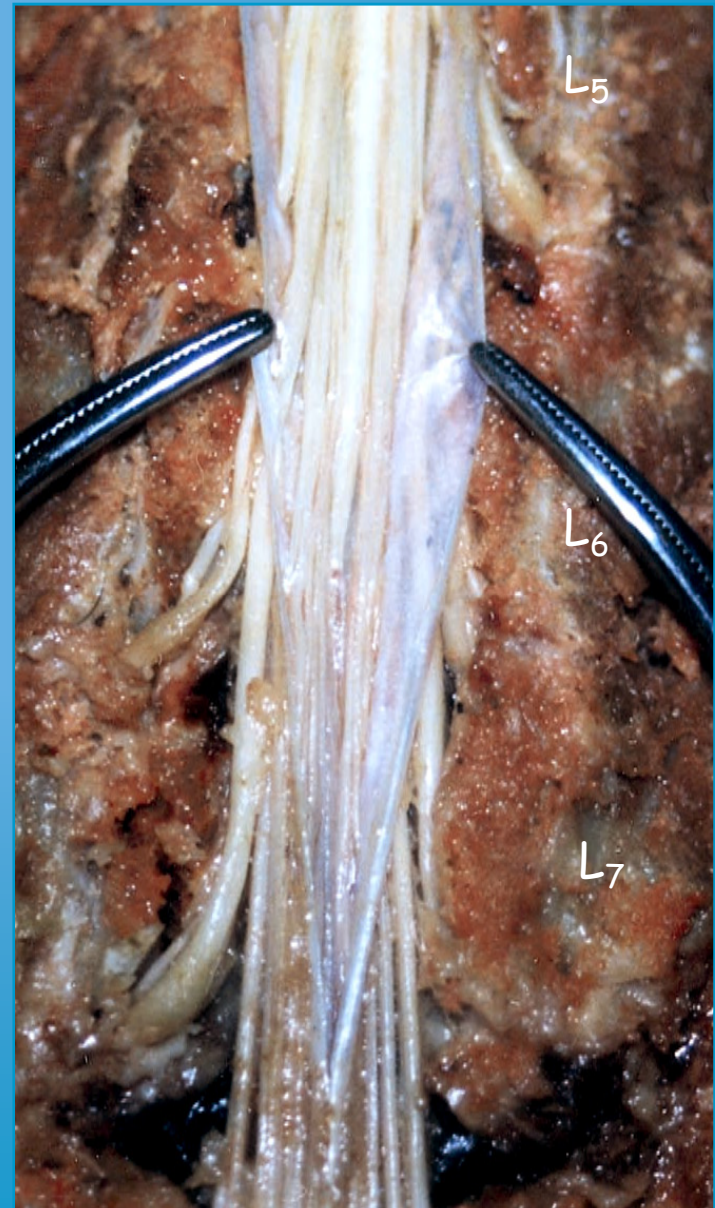
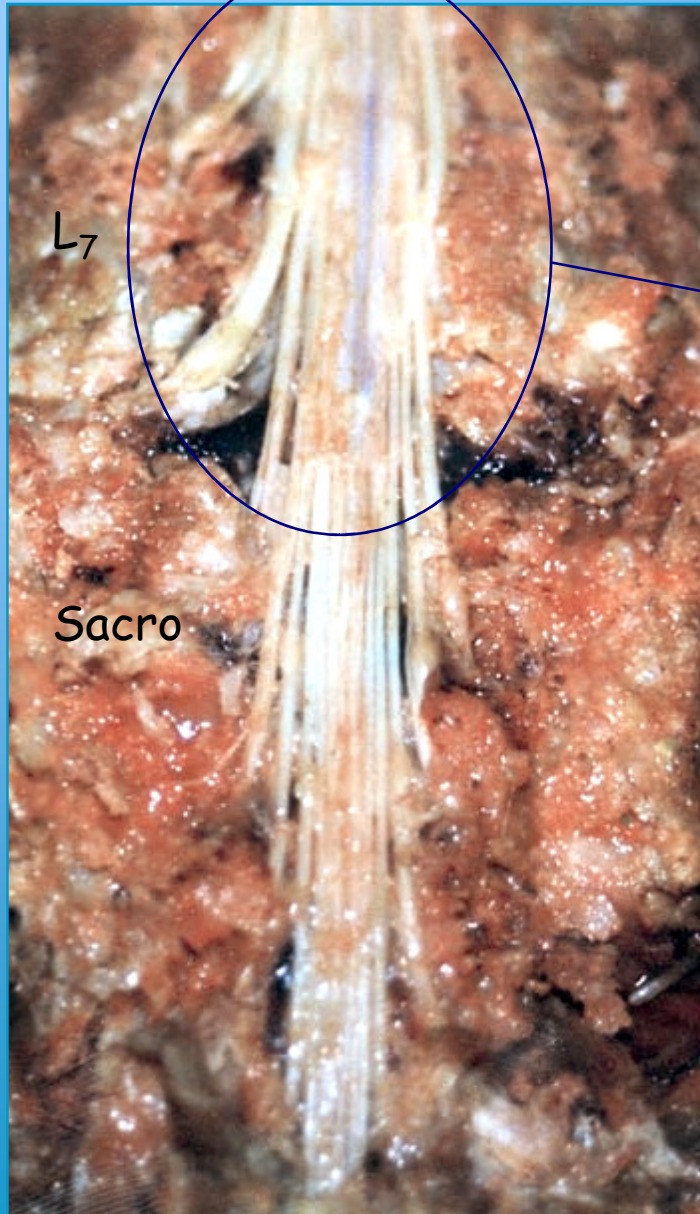
seno venoso

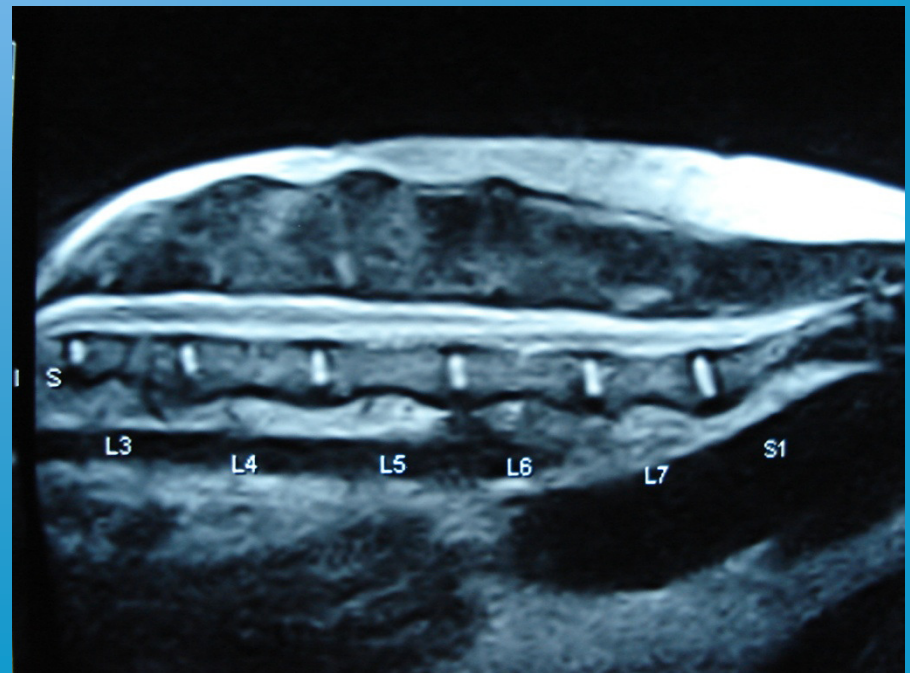
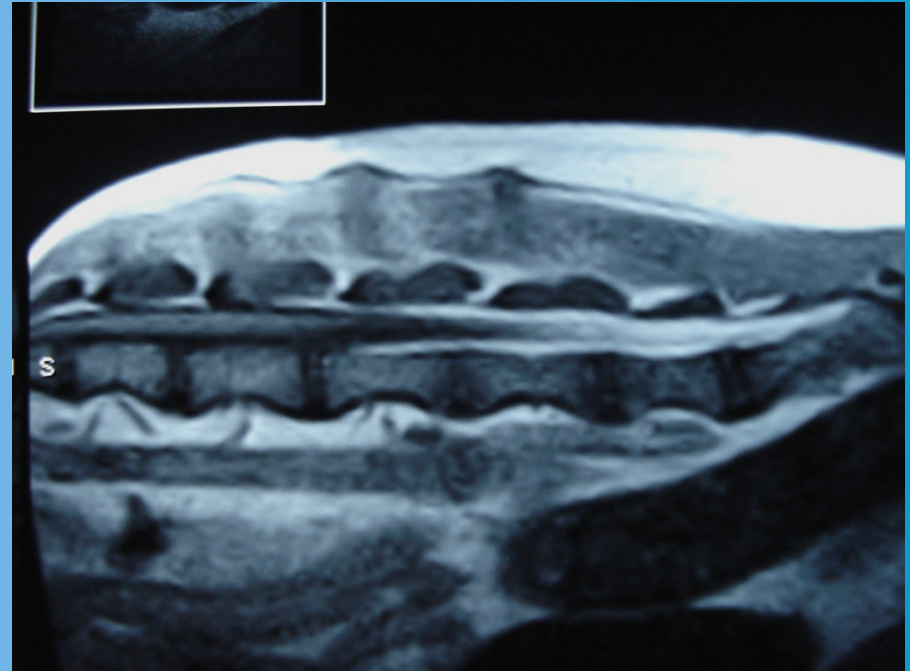
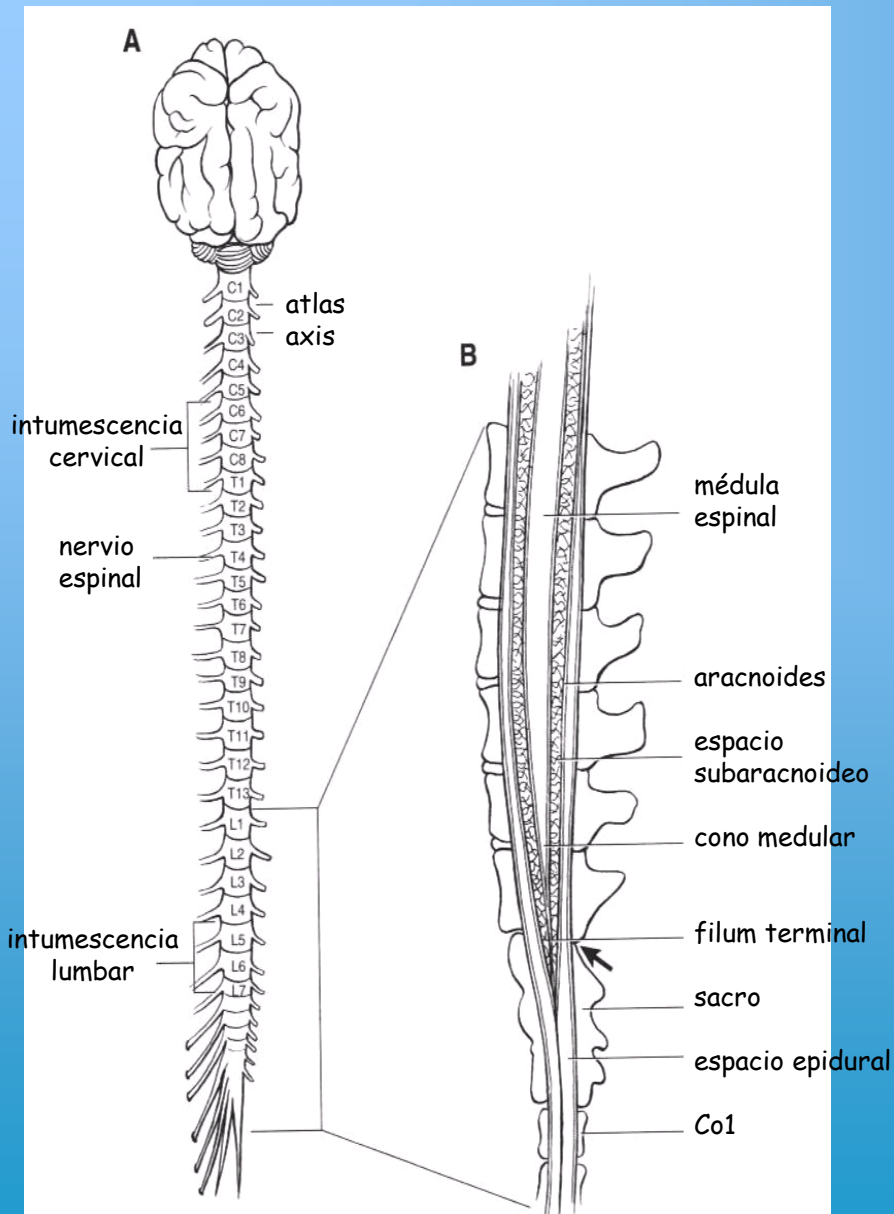
cuerpo vertebral

núcleo pulposo

anillo fibroso



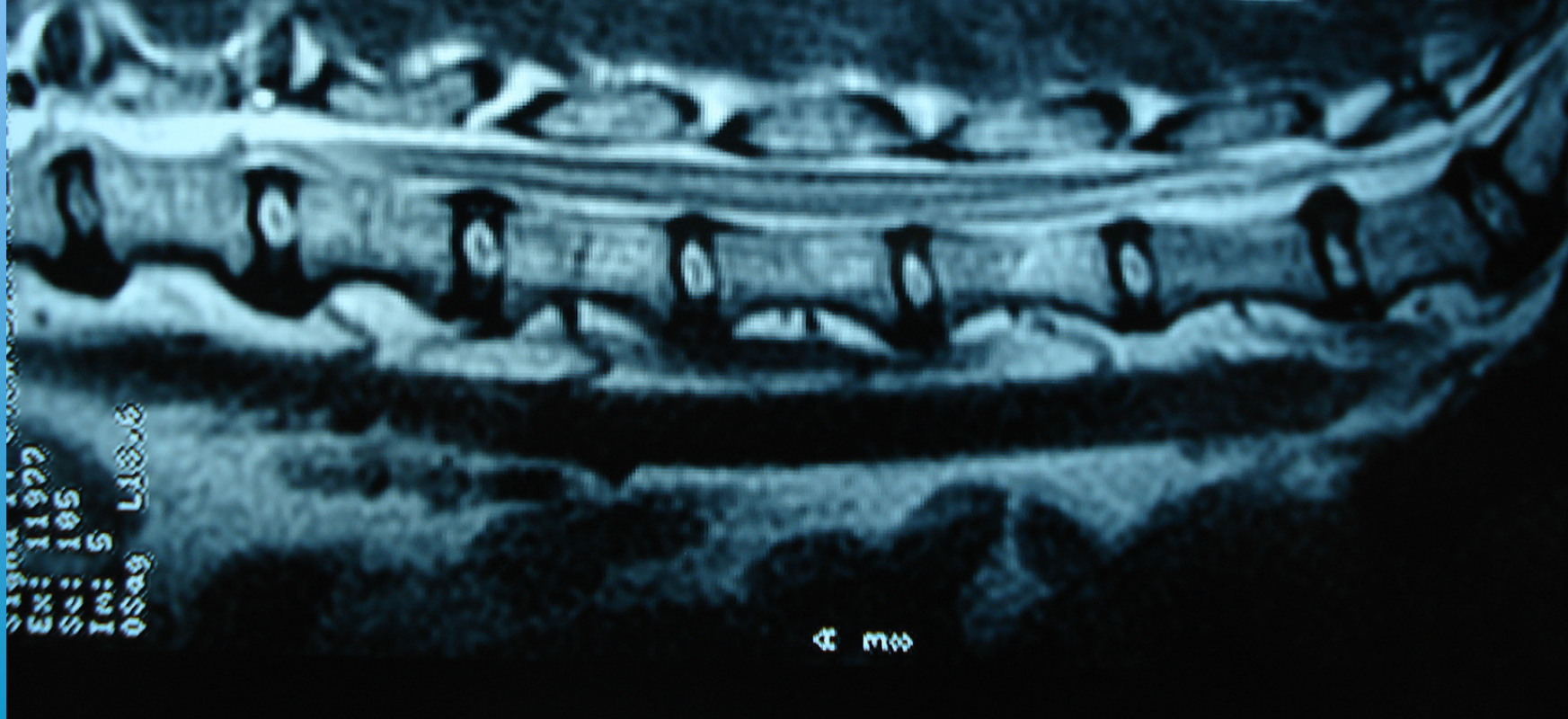




EX: 11977
SE: 185
IM: 5
08ag L18.6

CAN 9999
F 9
02 Jun 2007
11:18:43 PM

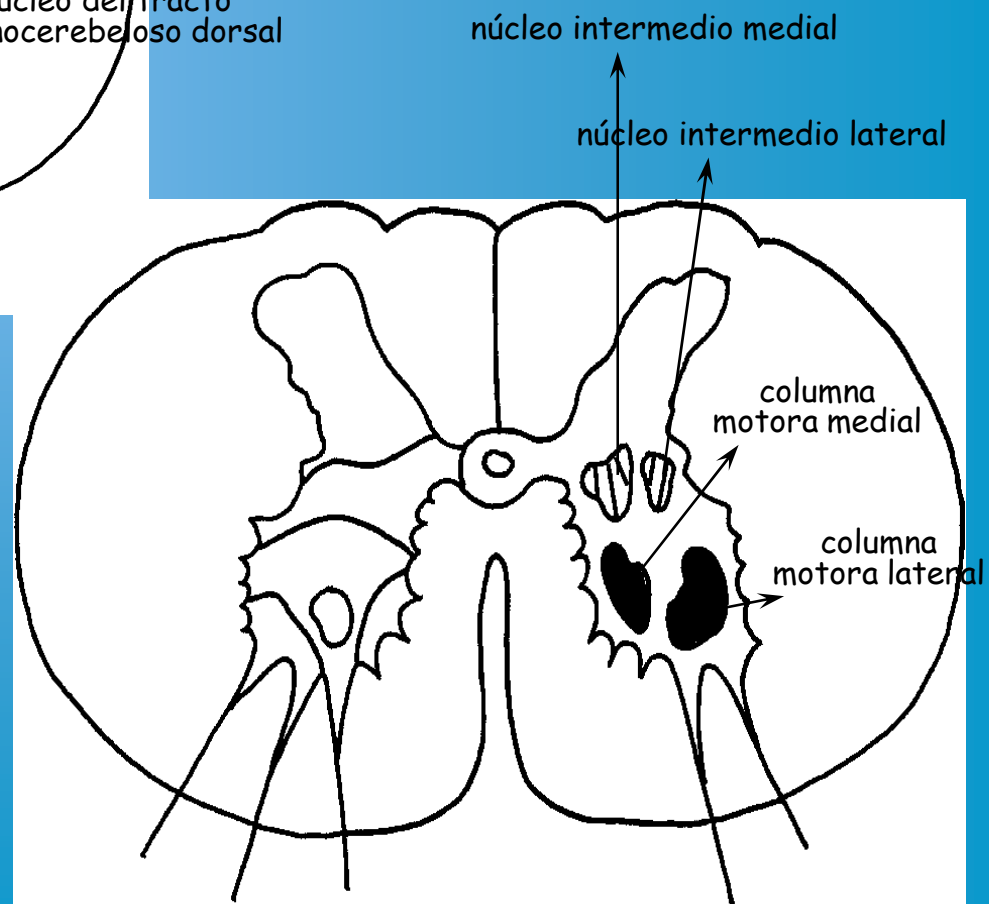
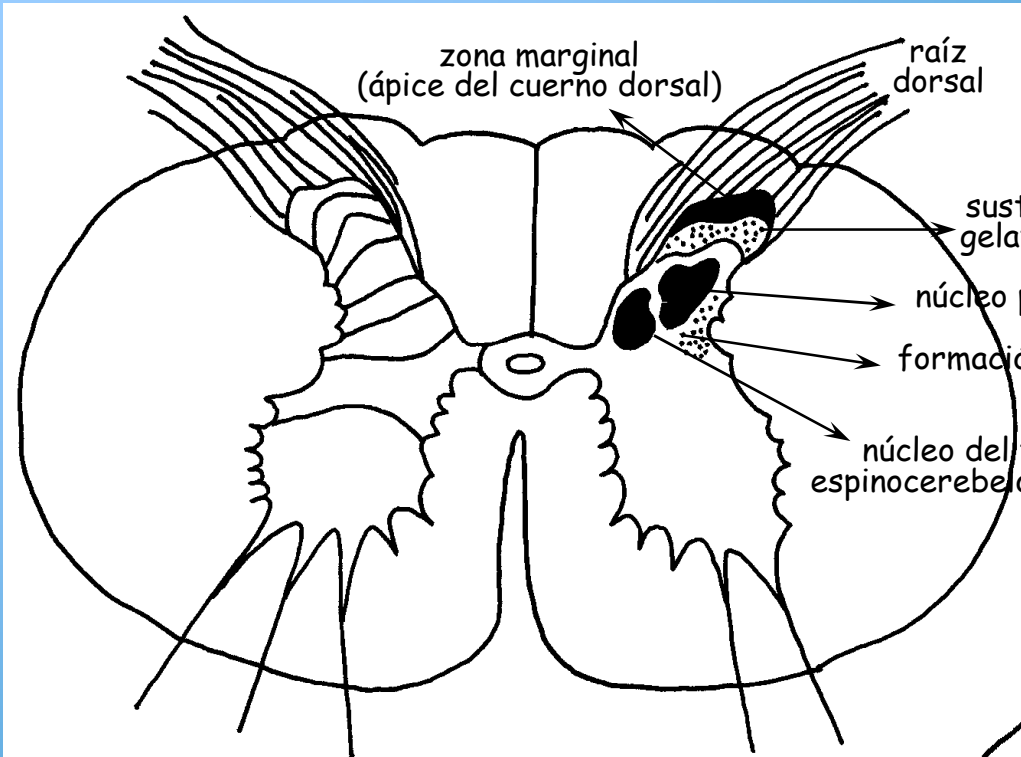
EX: 1195
SE: 185
IM: 5
08ag L

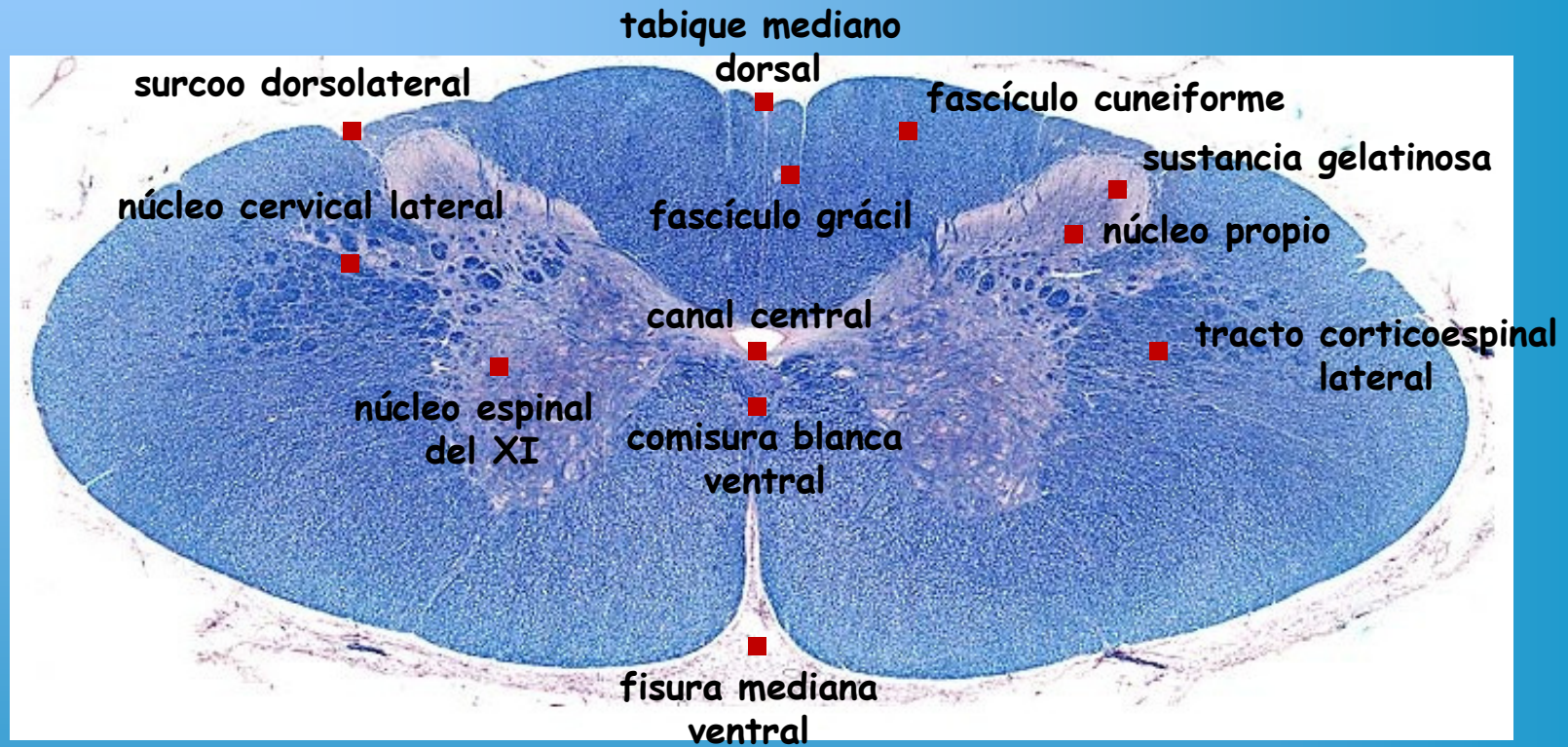


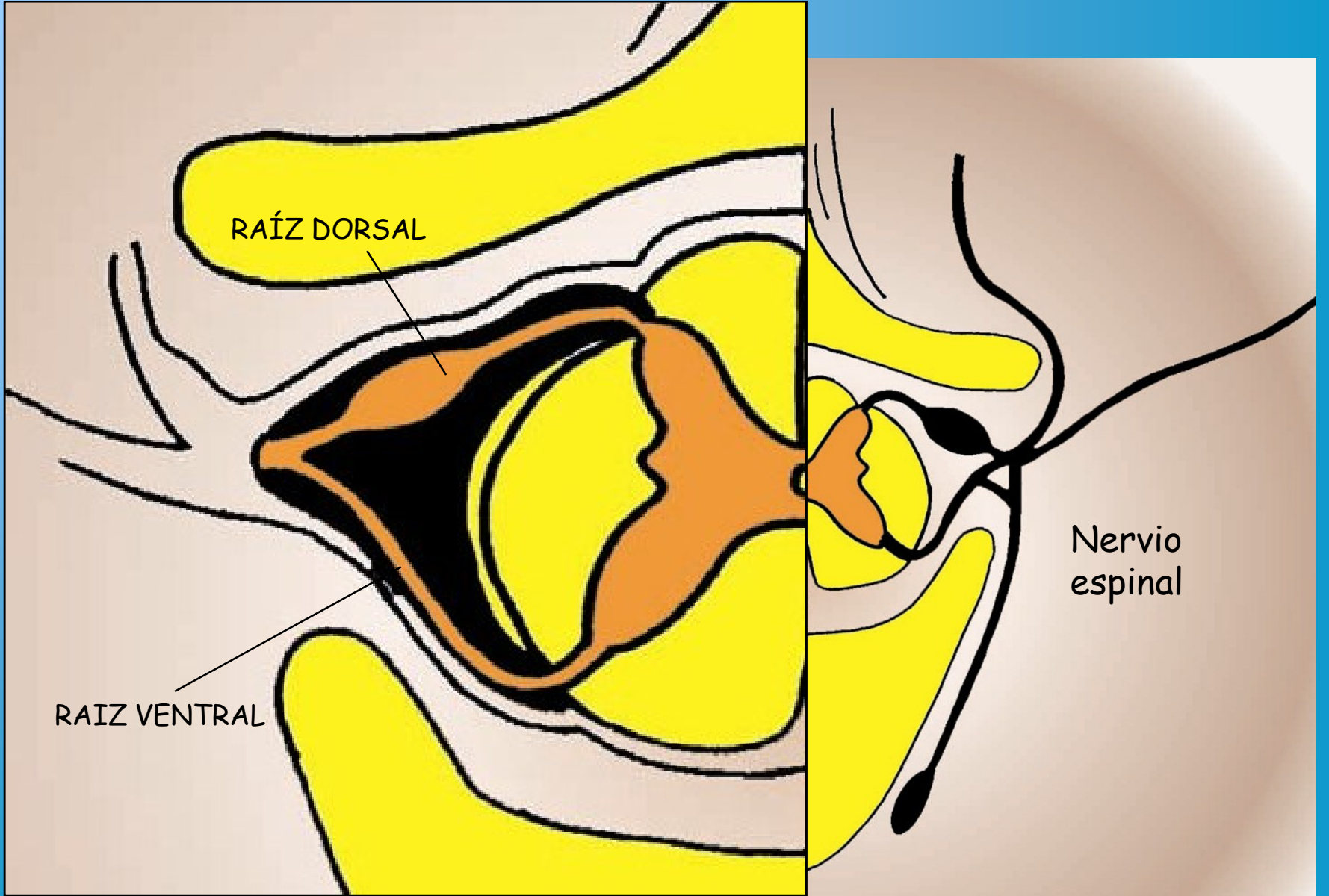
← m00

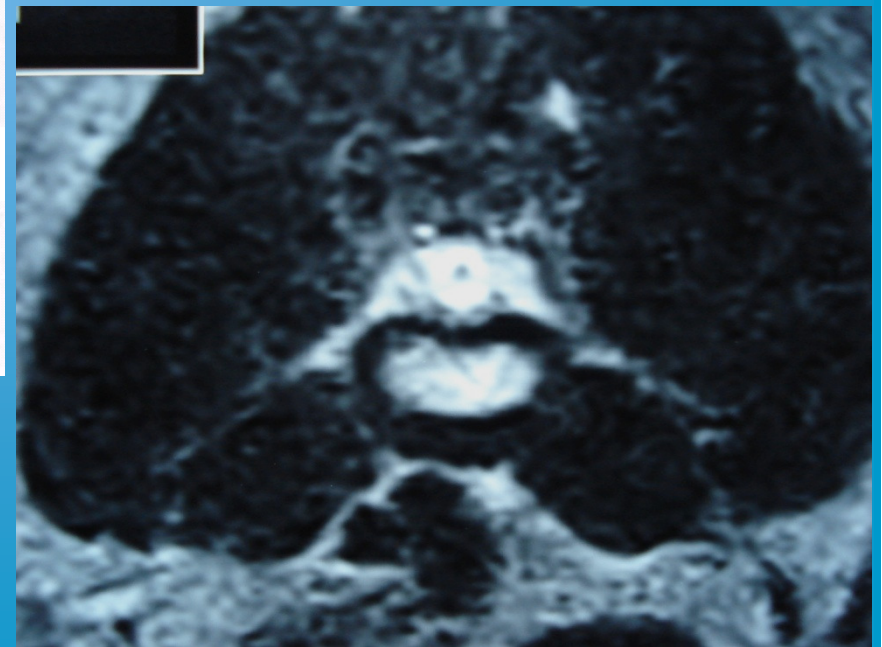
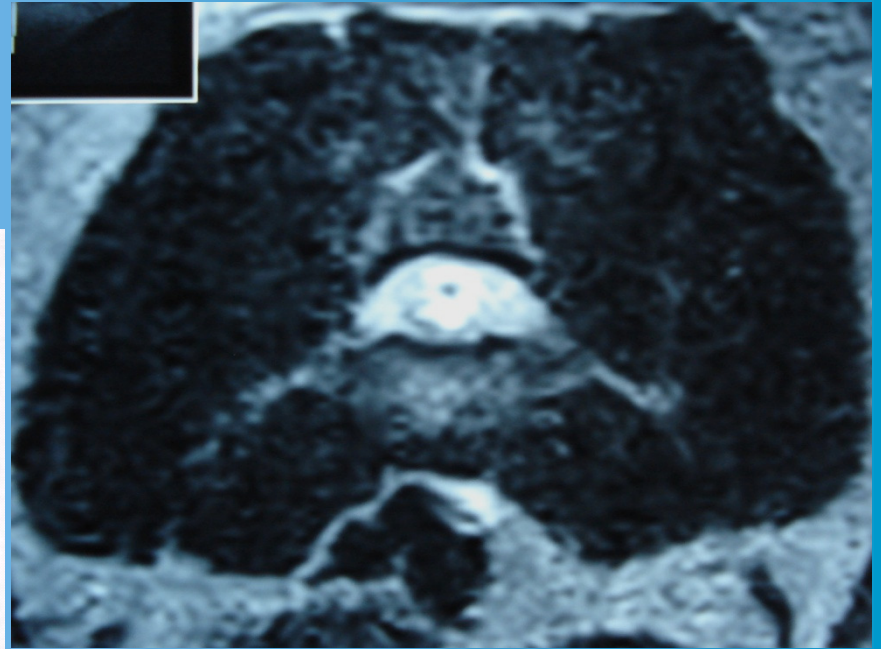
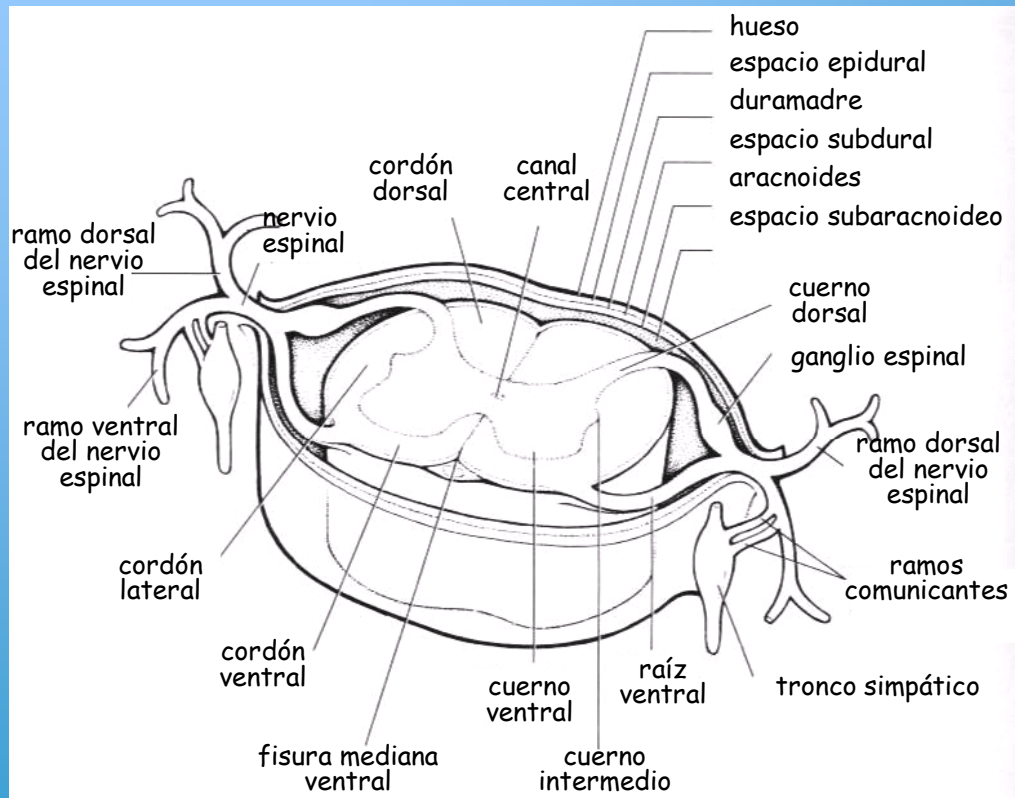
a. 55

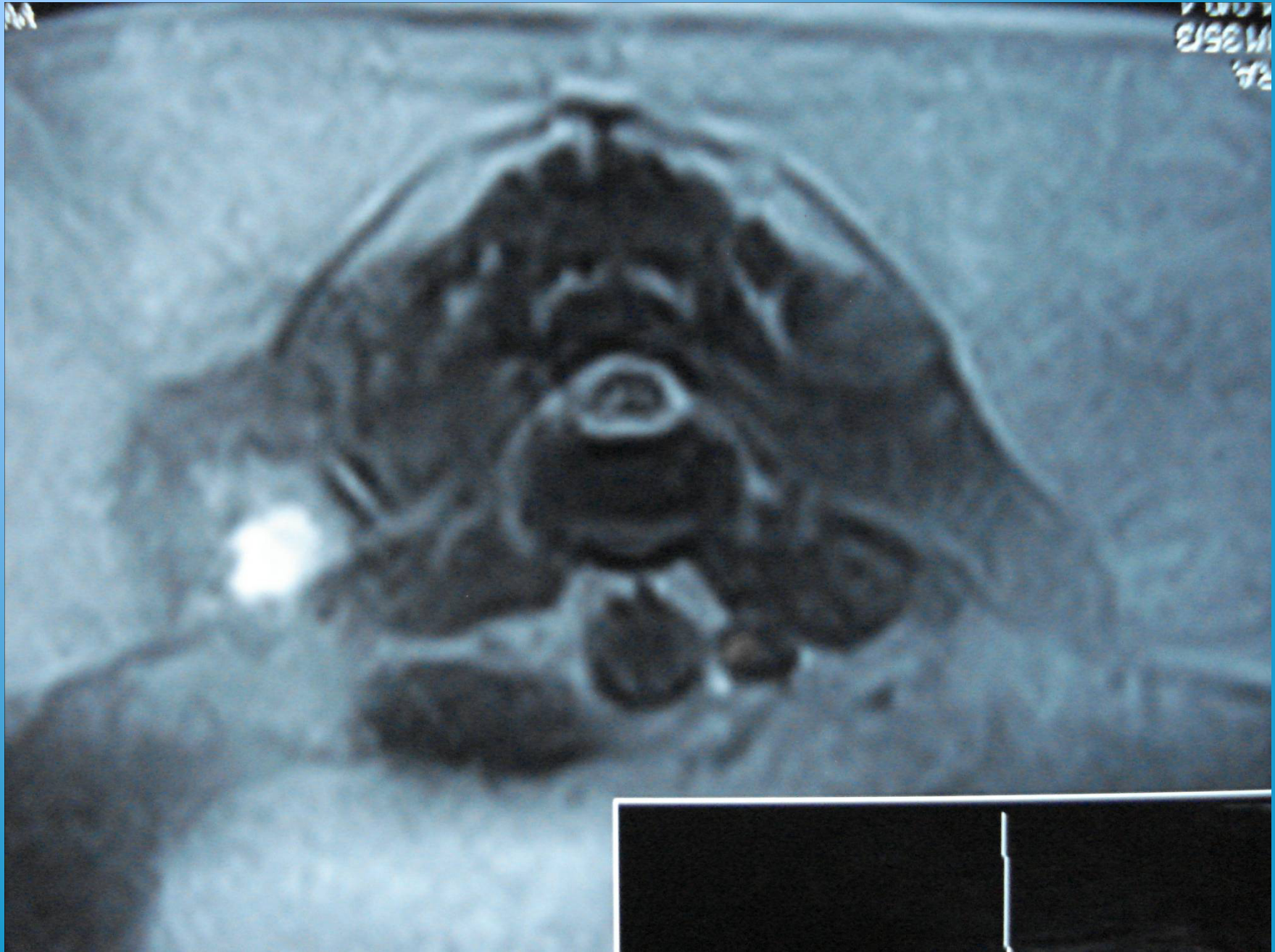
← m00

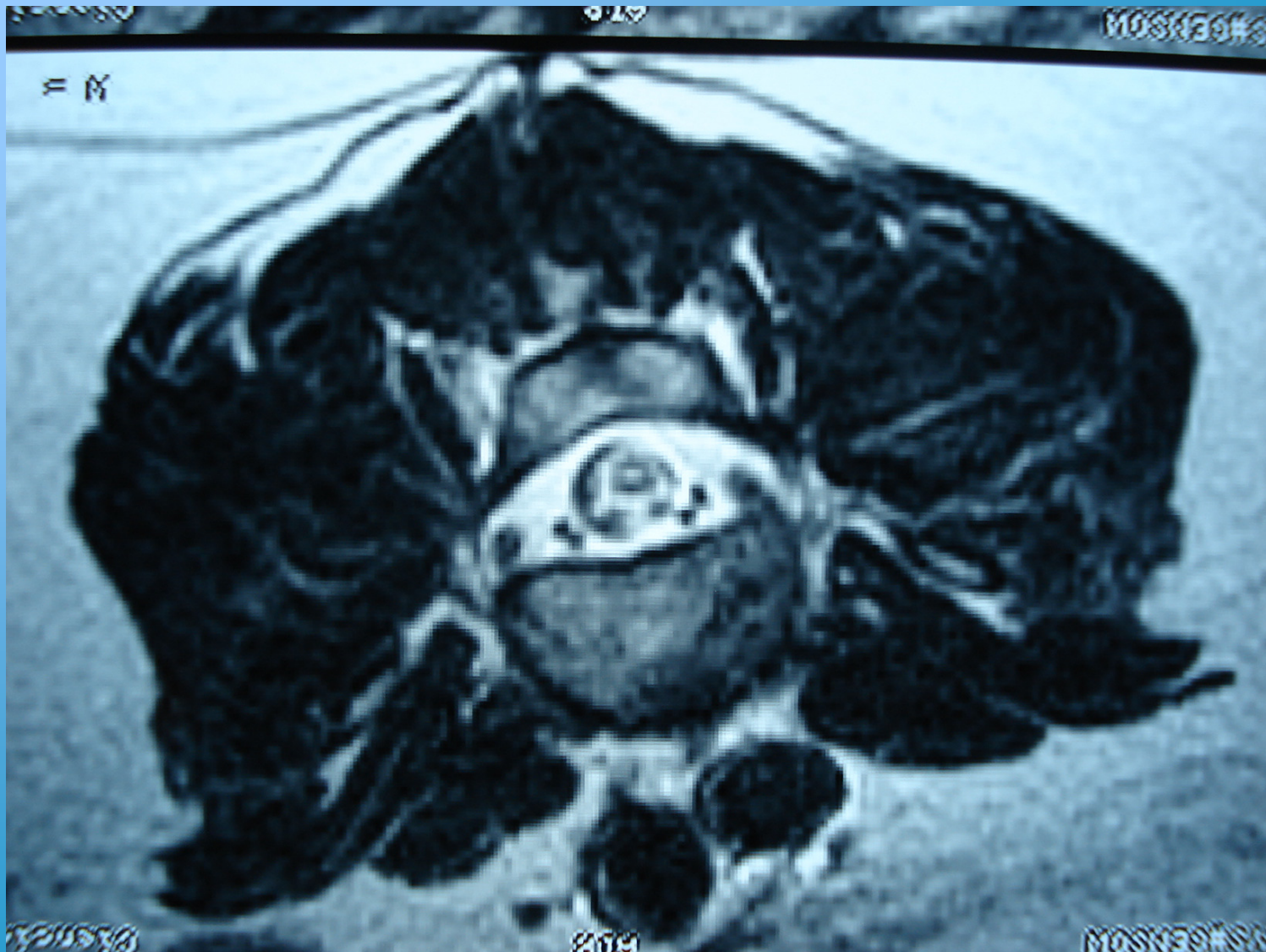




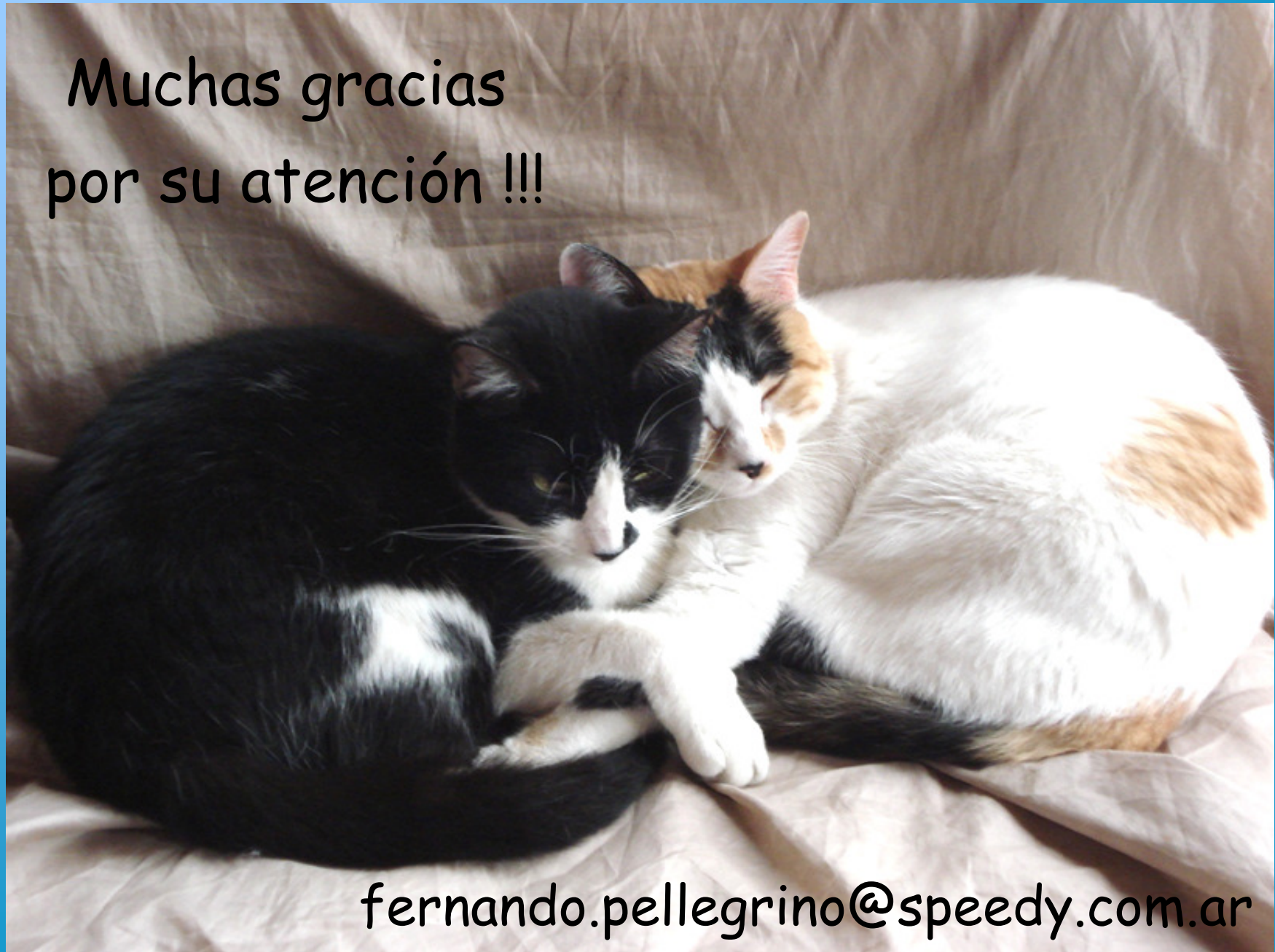







Muchas gracias
por su atención !!!



fernando.pellegrino@speedy.com.ar